

# ST STEPHENS COLLEGE BAJJA

## S.5 TOPICAL BIOLOGY NOTES

Dear s.5 students, please download and copy out or print a copy of this write-up.

Where need be please make reference to any of the biology textbooks you can easily access.

Hopefully that by now at least each one of us has a personal copy of any of those different books we said are very relevant in our study.

Remember, as a biology student you should never allow a single day, go without u interacting with a biology textbook, for we should be like soldiers who believe in *training hard and fighting easy*

*This pandemic will come to pass and soon we will be back to our normal business.*

## HISTOLOGY (TISSUE ORGANISATION)

A tissue is a group of cells linked together to perform a particular function. These are two main types of tissues i.e. plant and animal tissues.

### ANIMAL TISSUES

There are 4 major groups of animal tissues i.e.

- i) Epithelial tissue
- ii) Connective tissue
- iii) Muscular tissue
- iv) Nervous tissue

### EPITHELIAL TISSUES

They are comprised of a single or several layers of cells held together by intercellular substances. The bottom layer of cells is attached to a basement membrane made up of **collagen fibres**.

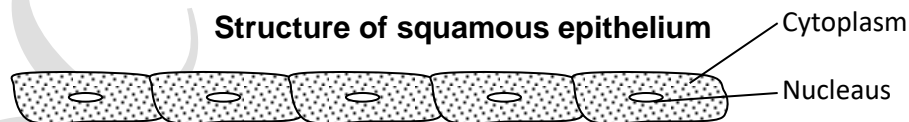Epithelial tissue cover inner and outer surfaces where they always have a protective function. The cells may be linked by keratin to resist abrasion and divide rapidly to replace cells that are worn out.

When diffusion is to take place across a surface, the epithelial layer has to be thin. Many epithelial are specialized for absorption e.g. in intestines and for secretion e.g. salivary gland.

#### Summary of animal epithelial tissues SIMPLE EPITHELIAL TISSUE

##### 1. Squamous epithelial (pavement epithelial):

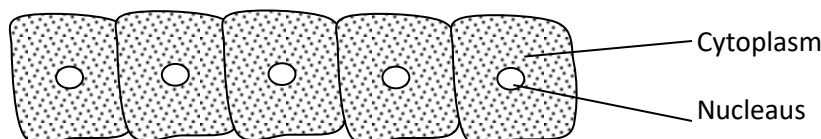
Cells form a single layer attached to a basement membrane. In surface view, the cell outlines are irregular and closely packed. The cells are thin, shallow and flattened. Adjacent cells may be joined by strands of cytoplasm. Such epithelia form structures and surfaces over which diffusion can occur hence are important in the **alveoli of the lungs**, **Bowman's capsule** and in **capillary walls**. Their smooth surface provides a friction free lining for blood vessels.



##### 2. Cuboidal/cubical epithelial

Such epithelium has a secretory function in glands like thyroid, sweat and salivary glands. It also has a non-secretory function e.g. the lining of the kidney collecting tubules, proximal and distal convoluted tubules, pancreatic ducts, etc. Its cells are cuboidal and form a single layer attached to a basement membrane.

##### Longitudinal section of cuboidal epithelial

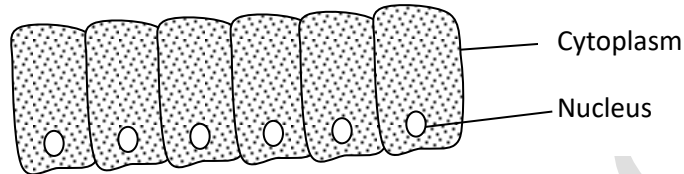


### 3. Columnar epithelium

These are tall and narrow cells with a nucleus near their base. Their surface area is increased by micro villi at the free end. Such cells are mostly found in areas that have an absorptive role.

Secretory goblet cells are found within the columnar cells. This tissue is found lining the digestive system where secretion of mucus and absorption of food takes place. It is also found lining the kidney ducts and the thyroid glands.

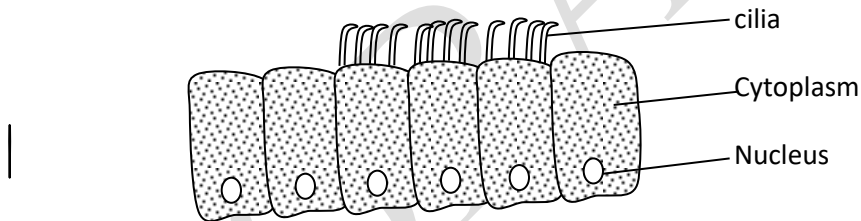
#### Longitudinal section



### 4. Ciliated epithelium

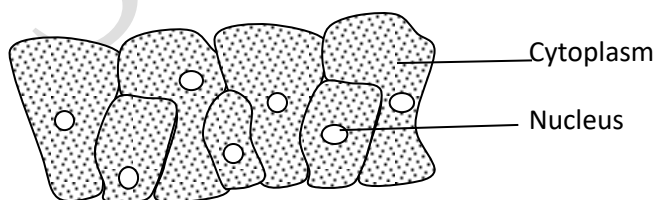
It comprises of columnar cells with cilia at their free edges. They have many mucus secreting goblet cells present. The combination of mucus and cilia allows substances to move through ducts e.g. in the oviduct, trachea, spinal cord, bronchus and bronchioles where it moves materials from one location to another.

Longitudinal section



### 5. Pseudostratified epithelium

The nuclei of this type of epithelium appear to be at several different levels because not all the cells reach the free surface. Nevertheless, the epithelium is still one layer or one cell thick with each cell attached to a basement membrane. It is found lining the urinary tract and respiratory passages e.g. bronchi.



## COMPOUND EPITHELIAL

### 1. Stratified epithelium

It is made of many layers of cells and therefore thicker than the simple epithelium and forms a germinating layer and they undergo cell division. As new cells form, older ones are pushed near to the surface changing shape and flattening to form squamous. The squamous may remain un keratinized as in the oesophagus or may be heavily thickened with keratin (cornified) e.g. the skin where there is a dead layer of cells like those found lining inside the mouth and vagina. Therefore they are for protection from abrasion to areas exposed to wear and tear.

## **2. Transitional epithelium**

It is found in structures which must stretch e.g. the urinary bladder and parts of the kidney. It comprises of 3 or 4 layers of cells which may be flattened towards the surface which are not shed like those of the stratified epithelium. Transitional epithelium lacks a basement membrane.

The functions of transitional epithelium include:

- ✓ By changing the shape, the transitional epithelium allows the expansion of the organ.
- ✓ It prevents the loss of water from blood to urine.
- ✓ Due to its thickness, it prevents the urine from escaping into the surrounding tissue.

### **GLANDS - GLANDULAR EPITHELIUM**

#### **1. Based on the kind of secretion and the duct present, glands are of two types;**

- i) Exocrine glands: these pour their secretions through the ducts to their respective sites of action e.g. salivary, tear intestinal and gastric glands. Their secretions are called enzymes.
- ii) Endocrine glands: these do not possess ducts and pour their secretions directly into the blood stream. Their secretions are known as hormones.

#### **2. Based on number of cells, the glands are of 2 types;**

- i) Unicellular: an individual epithelial cell is modified into a glandular cell as in goblet cells.
- ii) Multicellular: number of glandular cells aggregate to form a multicellular gland. Multicellular glands can further be divided into simple or compound glands e.g. sweat glands.

#### **3. Based on the shape and complexity, the exocrine glands are of 2 main types; simple and compound glands which may further be modified.**

- i) **Simple glands:** these have a single unbranched duct. The secretory part could be in the form of (called tubular) or sacs (alveolar). These could be coiled or uncoiled, branched or unbranched. Various forms of simple glands are given below;

**Simple tubular**  
e.g. crypts of Lieburkuhn in intestine

**Simple coiled**  
e.g. sweat glands

**Simple branched tubular** e.g. gastric glands and Brunner's glands of intestine.

**Simple secular/alveolar**  
e.g. mucous secreting glands in frog skin.

**Simple branched alveolar gland;** number of sacs opening in same duct e.g. sebaceous glands.

- ii) **Compound glands:** these have number of ducts forming a branching pattern.

**Compound tubular glands**  
e.g. salivary glands.

**Compound alveolar/sacular** e.g. mammary glands, pancreatic glands.

**Compound tubular alveolar** e.g. parts of salivary and mammary glands.

#### 4. Based on the mode of secretions, the exocrine glands are of 3 types;

- i) **Merocrine glands:** the secretions produced within the cell are discharged on its cell surface without losing any of its cytoplasm. E.g. goblet cells, pancreatic glands and sweat glands.
- ii) **Apocrine glands:** in these glands, the cell loses a part of its cytoplasm while releasing its secretions. The secretions are stored in the apical part of the cell which bursts open to release the contents e.g. mammary glands.
- iii) **Holocrine glands:** the entire cell breaks down in order to release its secretions which extrude from the epithelial surface e.g. sebaceous glands.

#### 5. Based on the form of secretion, glands are of 3 types.

- i) Mucous glands: secretion is in form of viscous mucous fluid. They are called mucocytes.

- ii) Serous glands: secretion is clear, watery fluid containing enzymes. They are called serocytes.
- iii) Mixed glands: secrete both.

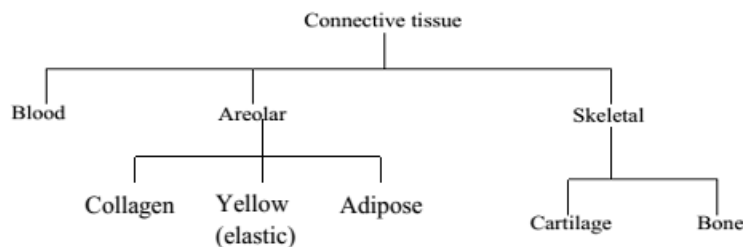
### Functions of epithelial tissues

The epithelial tissues serve the following functions; protection, secretion, absorption, exchange of materials/gases and sensory.

## CONNECTIVE TISSUE

It is composed of a variety of cells embedded in a large amount of intercellular substance called matrix. Connective tissues develop in the embryonic mesoderm. It provides the main supporting tissues in form of blood. Other connective tissues insulate the body e.g. adipose tissue.

### Summary of the connective tissue



### 1. AREOLAR TISSUE

This is one type of connective tissue found all over the body i.e. beneath the skin connecting organs together and filling spaces between adjacent tissues.

Areolar tissue consists of a glycoprotein matrix containing four types of cells and two types of protein fibres. The areolar cells include:

- i) **Fibroblasts:** These are long flat cells which synthesize collagen and elastic fibres.
- ii) **Mast cells:** These are amoeboid in shape or oval shaped and contain granular cytoplasm. They secrete fats filled cells and an anticoagulant or ground matrix or substance and macrophages.
- iii) **Fat cells:** These are fats storing cells which accumulate fats in the body structures to form the adipose tissue.
- iv) **Macrophage or histocytes:** These are amoeboid cells which are large which ingest a number of foreign particles hence are important in defense against foreign bodies. The fibres present in areolar tissue give it its strength and toughness.

There are two types of fibres in areolar tissue:

- a) The unbranched collagen fibres/white fibres: these appear parallel to each other and are arranged in bundles. They are mainly found in tendons.
- b) Branched elastic fibres/the yellow fibres: these form a dense network of fibres. They cross the matrix. The structures are stretchable and are found in ligaments.

### **Transverse section through areolar tissue**

FA page 36 fig.3.5

Three other types of connective tissues are derived from areolar tissue and only differ from each other in the structures present in the matrix. These include;

#### **a) Collagen tissue/white fibrous tissue:**

This consists of glycoprotein matrix containing densely packed collagen fibres. Collagen tissue has fibres which are inelastic and have a high tensile strength. They are found in the tendons where they attach muscles to bones. They are found in the Dura matter of the brain and also in the cornea of the eye.

#### **b) Elastic tissue/yellow fibrous tissue:**

This consists of a glycoprotein matrix containing only elastic fibres. It is strong and elastic. Such tissue is found in ligaments where it binds bones to other bones. It is also found around the walls of arteries and it is also found as a component of the lungs and associated air passages as well as in the great cords of the neck.

#### **c) Adipose tissue (fatty tissue):**

This contains closely packed fat filled cells known as adipocytes. Its functions are storage of fats and it is a site for energy production. The fats are deposited in a number of parts of the body e.g. the dermis of the skin where it insulates the body against heat loss. There are two types of adipose tissue;

##### **i) White adipose tissue:**

The white adipose tissue is called so because the cells appear white due to accumulation of fats. It is distributed throughout the body particularly the deep layers of the skin.

##### **ii) Brown/yellow adipose tissue:**

This is commonly in young mammals and some hibernating mammals. It is important in temperature regulation. It is supplied within blood capillaries and appears red. It differs from the white because of;

- ✓ It's coloured and has limited location in the body e.g. it is found around the neck.
- ✓ The fats in brown remain as small droplets i.e. do not form big globules.
- ✓ The nucleus of the brown remains centrally placed.

## 2. BLOOD TISSUE

In blood, the matrix is the watery plasma which carries a variety of different cells. The cells present include:

### i) **Erythrocytes (RBC):**

These are biconcave in structure. They lack nucleus and are formed in red bone marrow.

Their main function is transport of oxygen within the body. They contain red pigment haemoglobin which combines with oxygen to form oxy-haemoglobin; the form in which oxygen is transported in the body.

### ii) **Leucocytes (WBC):**

- ✓ They are larger and nucleated.
- ✓ Most of them are made in the bone marrow while others are made in the lymph nodes and in the thymus gland.
- ✓ Their main role is defense of the body.

**There are two types of white blood cells, i.e.**

#### a) **Granulocytes:**

They have granular cytoplasm with a lobbed nucleus. They engulf bacteria by phagocytosis.

#### b) **Agranulocytes:**

They have a non-granular cytoplasm with a compact nucleus. Most of them also ingest bacteria. They are produced from the lymph nodes and thymus glands and are known as lymphocytes. Their function is to produce antibodies.

### iii) **Platelets (Thrombocytes)**

These are tiny cell fragments important in blood clotting.

## Formation of blood cells

The process of formation of erythrocytes is known as haemopoiesis and the tissue which forms then is known as haemopoietic tissue.

In the fetus, erythrocytes are formed in the liver and spleen. In an infant all bones contain haemopoietic tissue. In adults, erythrocytes are formed in the bone marrow of the bones of

the pelvis, sternum, vertebrae, clavicle, scapula and skull. During the process of formation of cells, the bone marrow undergoes two major changes;

- i) The amount of haemoglobin increases in the cytoplasm.
- ii) There is progressive loss of nuclear material and reduction in the size of the cell. A mature erythrocyte does not contain the nucleus and almost the entire cell is filled with haemoglobin.

The erythrocytes are nucleated at infant/fetal stage.

Iron and proteins form the basic raw material for haemoglobin synthesis.

Vitamin B<sub>12</sub> and folic acid stimulate the maturation of erythrocytes.

WBC like lymphocytes are formed in the thymus gland and lymph nodes whereas the other types of WBC are formed in long bones e.g. the limb bones which have white bone marrow.

### **Questions:**

**1) Outline the differences between RBC and WBC.**

**2) Outline the adaptations of WBC and RBC to their functions.**

## **3. SKELETAL TISSUE**

This is made up of cartilage and bone.

### **CARTILAGE**

The matrix of cartilage is made up of chondrin and chondrocytes which are embedded in it. It has fibres composed of collagen. The structure of cartilage is hard but flexible and found at the ends of bones, respiratory passages e.g. trachea and parts of the ear. It comprises the skeleton of cartilaginous fish e.g. sharks. Cartilage can contain a large number of collagen fibres making it stronger and less flexible; such types of cartilage make up the intervertebral discs.

### **Types of cartilage**

#### **1. Hyaline cartilage**

The simplest form of cartilage is known as hyaline cartilage which consists of only chondrin matrix and chondroblasts which secrete it. It is glassy in appearance and has very few fibres. This type of cartilage forms the basis of growth and development in embryos. It also makes or forms parts of the respiratory tracts like the trachea, parts of the ribs and ends of bones and the nose.

Hyaline cartilage is bounded by fibrous layer known as perichondrium in which there are blood vessels. It reduces friction in areas where it is found.

Transverse section through the hyaline cartilage

## 2. Fibrous/tensile cartilage

This has got many fibres not as flexible and elastic as those of hyaline. It is adapted to resist compression due to presence of large bundles of collagen fibres. Its functions are to allow flexibility and reduce friction. It is also found in vertebral discs and around the pubic symphysis. It also provides a cushioning effect around areas it occurs.

## 3. Elastic cartilage

This has many yellow fibres. It is more flexible and elastic than all the other types of cartilage. It is found in the epiglottis, respiratory tract, the nose and the pinna of the ear supporting the Eustachian tube and the external auditory parts.

## THE BONE TISSUE

The ostein matrix of bone is made up of collagen together with inorganic substances e.g. calcium, magnesium and phosphorus. Such components are arranged in concentric circles called lamellae which surround the Haversian canal containing an artery, lymph vessels and nerve fibres.

### Structure of a bone:

Each bone is enclosed in a layer of white fibrous connective tissue called the **Periosteum**. It is through the Periosteum, the blood vessels and nerves pierce in. In a bone, the matrix is arranged in concentric circles called **lamellae**. In between the lamellae are present, number of living bone cells called **osteoblasts** or **osteocytes**, in the fluid-filled cavities called **lacunae**. Osteoblasts are active bone cells while osteocytes are inactive osteoblasts. Each lacuna has fine cytoplasmic extensions called **canaliculi** which pass through lamellae and make connections with other lacunae.

### Structure of a compact bone:

A compact bone has number of Haversian canal system arranged concentrically. The Haversian canals are present transversally as well as longitudinally. They form an interconnected network communicating with the bone marrow as well. In the centre of a compact bone is present a bone marrow cavity lined by Endosteum.

### Transverse section of compact bone

Diagram in FA page 38 fig. 3.7 A

## Longitudinal section through a bone

### Ossification (development of bone from cartilage)

This is the process by which cartilage change to bone. It is also referred to as endochondrial ossification.

- ✓ It begins with rapid cell division and the cells arrange themselves in parallel column in the longitudinal axis of bone to be formed.
- ✓ A primary ossification center is then established in the middle/center.
- ✓ Chondroblasts arrange in rows, become hypertrophied and let down calcium salts in the matrix.
- ✓ The process starts from the centre and works its way outwards.
- ✓ Another region of ossification occurs in the shaft where osteoblasts let down fibres on the surface of cartilage.
- ✓ The region then becomes calcified gradually forming compact bones.
- ✓ Osteoblasts then erode through the bone forming channels of blood vessels and nerves.
- ✓ Osteoblasts deposit bone salts in the spaces created and let down a matrix in layers.
- ✓ Osteoblasts are then enclosed in lacunae interconnected by canaliculi.

### Differences between bone and cartilage

BONE	CARTILAGE
Matrix is ostein	Matrix is chondrin.
Matrix is firm, inelastic and rigid.	Matrix is firm, elastic and flexible.
Surrounded by periosteum.	Surrounded by perichondria.
Blood vessels and nerves present.	Blood vessels and nerves absent.
Have osteoblasts that form the osteocytes.	Has chondroblasts that form the chondrocytes.

Osteoblasts form the ostein matrix.	Chondrocytes form the chondrin matrix.
Have inorganic materials like Ca and P ions.	Lacks the inorganic molecules.
Marrow cavity is present in long bones.	Marrow cavities absent.
Have concentric circles of lamellae with lacunae and canaliculae.	Lacks the lamellae, lacunae and canaliculae.
Osteoblasts are star shaped.	Chondroblasts are spherical.
Relatively metabolically active.	Not metabolically active.
Osteoblasts are arranged in concentric circles.	Chondroblasts are scattered randomly in the matrix.
Can manufacture blood cells from the bone marrow.	Cannot manufacture blood cells.
Matrix has haversian canals.	Matrix has no canals.
Has a secretory function.	No secretory function.

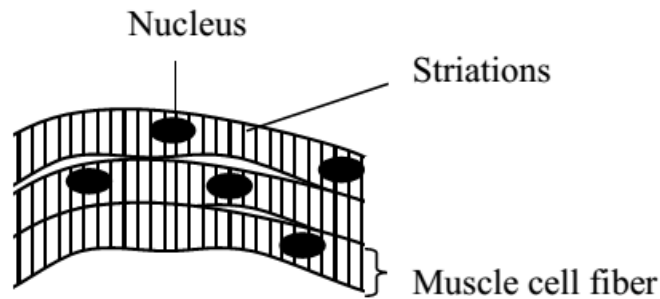
### MUSCULAR TISSUE

There are 3 main types of muscular tissue all made up of cells and fibres which are capable of contraction. They are derived from the mesoderm of the embryo. They include:

- 1) Voluntary (skeletal/striated/stripped) muscles.
- 2) Involuntary (smooth/unstriated/unstripped) muscles.
- 3) Cardiac muscles.

#### Voluntary muscles

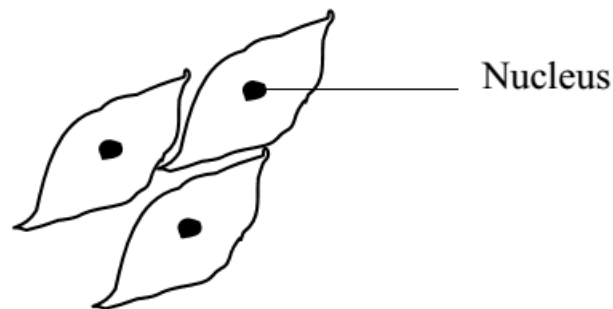
- ✓ It consists of numerous multi-nucleate cylindrical muscle fibres.
- ✓ The muscle fibres have alternate light and dark band or striations due to the banding pattern and arrangement of thin filaments called myosin filaments.
- ✓ The muscle fibres do not extend the whole length of the muscle but consists of functional units called **sarcomeres**.
- ✓ Each multi-nucleate muscle fibre is contained in a plasma membrane called the **sarcolemma** surrounding cytoplasm called **sarcoplasm**.
- ✓ The sarcoplasm contains thousands of myofibrils with characteristic striations, numerous mitochondria and smooth endoplasmic reticulum.
- ✓ Groups of fibres are bound by a thin film of connective tissue and the whole muscle is bound by a sheath of connective tissue.
- ✓ Blood vessels run longitudinally besides the fibres with many capillary connections.
- ✓ Every muscle cell is served by a motor nerve ending in a motor end plate.
- ✓ Its contractions are quick, powerful and voluntary with a short refractory period.
- ✓ They are attached to the skeleton.



### Involuntary muscles

- ✓ It consists of densely packed and elongated fibres running parallel to each other and bound by connective tissue.
- ✓ Each muscle fibre is a single cell containing one nucleus.
- ✓ There are numerous fine contractile fibrils.
- ✓ The fibrils are made up of thin actin filaments and thick myosin filaments.
- ✓ There are no cross striations in the muscle fibres.
- ✓ Each muscle fibre is served by its own nerve cell.
- ✓ These muscles contract rhythmically and do not fatigue easily.
- ✓ Their actin is controlled by the autonomic nervous system.
- ✓ They are found in the alimentary canal, walls of blood vessels and tubes of urino-genital system.

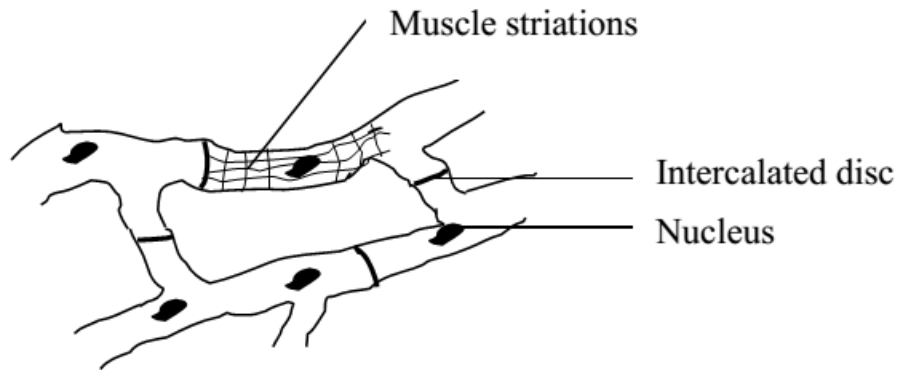
### Longitudinal section of the involuntary muscle from the alimentary canal



### Cardiac muscle

- ✓ It is a specialized muscle found inside a cell.
- ✓ It is capable of rhythmic contraction over a long period of time.
- ✓ Cardiac muscle is myogenic and its contraction is stimulated from within the heart itself.
- ✓ Each muscle cell has one or two nuclei.
- ✓ Their cells have a network arrangement which allows waves of contraction to spread rapidly over the heart.

### Transverse section through the cardiac muscle



### **Nervous Tissue**

It is derived from the embryonic ectoderm. It is comprised of closely packed nerve cells called neurons with little intercellular space. Neurons are bound together by connective tissue. *(To be covered under coordination)*

**Diagrams in BS page 193**

## **PLANT TISSUES**

They may be simple or compound.

### **SIMPLE PLANT TISSUES**

These consist of one type of cell in one layer. They are grouped according to the degree of thickening present in the cell wall. They are mainly of three types i.e. parenchyma, collenchyma and sclerenchyma.

#### **Parenchyma tissue**

- ✓ Its cells are usually spherical or elongated, living, with thin cellulose cell walls cells are loosely packed and have intercellular spaces in between.
- ✓ Parenchyma tissue stores food but when tightly packed and turgid, it provides support in herbaceous plants.
- ✓ Some are photosynthetic (parenchyma cells) are known as chlorenchyma.
- ✓ The epidermis is a specialized parenchyma capable of forming a waxy cuticle of cutin that prevents desiccation.
- ✓ Parenchyma also forms guard cells within the lower epidermis.
- ✓ In roots, cellular hairs near root tips are also made up of parenchyma tissue that assist in water uptake.

Transverse section of parenchyma tissue

### **Collenchyma tissue**

- ✓ It is made up of cell walls which have additional cellulose deposited in the corners to provide additional strength. These cells are living.
- ✓ They are elongated and important in growing since they can stretch.
- ✓ They are found just under the epidermis of the plant structures.

Transverse section of a collenchyma tissue

### **Sclerenchyma tissues**

- ✓ Mature sclerenchyma cells are dead and therefore not capable of growth. They develop fully when growth of the surrounding tissues is complete.
- ✓ Sclerenchyma cells are strengthened by lignin together with cellulose which is deposited to the primary cell wall where the cell contents are lost afterwards.
- ✓ In some places lignin is not deposited due to plasmodesmata. Such regions are called pits.
- ✓ Some sclerenchyma cells are spherical and known as sclerids which are found in small groups of seeds and fruits, cortex, pith and phloem. Their function is to toughen these structures.
- ✓ Elongated sclerenchyma cells called fibres provide the main supporting tissue of mature stems by forming a cylinder below the epidermis. They are also found in xylem and phloem.

### **Transverse section of sclerenchyma tissue**

Structure:

- ✓ It consists of fibres which are elongated cells and sclerids (torn cells) which are roughly spherical.
- ✓ Primary cellulose cell wall is thickened with deposits of lignin.

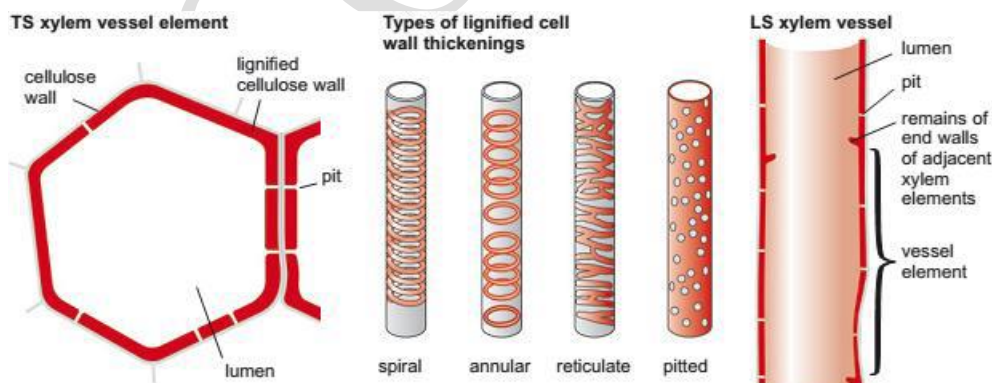
- ✓ Mature cells have an empty lumen hence are dead cells.
- ✓ Simple pits appear in the walls as they thicken and they interconnect adjacent cells.
- ✓ A secondary cell wall is built up in the layers.

## COMPOUND PLANT TISSUES

These are made up of different cells arranged in more than one layer. They include xylem and phloem tissues.

### XYLEM TISSUE

- ✓ It consists of parenchyma cells and fibres together with two specialized cells known as vessels and tracheids which are both dead.
  - ✓ Vessels and tracheids serve the role of support, water and mineral salt transport.
  - ✓ The type of vessel found depends on the degree and nature of the cell wall thickened.
- 
- ✓ In proto-xylem, lignin is deposited in rings or spirals such that the cell can still expand.
  - ✓ A vessel is formed from a chain of elongated cylindrical cells placed end to end.
  - ✓ In the course of development, the horizontal end walls breakdown so that the cells are in linkage with each other.
  - ✓ At the same time, the cellulose side walls become impregnated with lignin which makes them impermeable to water and salts.
  - ✓ At impregnation, the protoplasmic contents die leaving a hollow tube known as a vessel.
  - ✓ The xylem's lignified walls are perforated with pits where lignin fails to be deposited. These pits allow passage of water in and out of the vessel cavity.
  - ✓ In some cases, pits are covered by a lignified layer forming a torus kind of plug which controls passage of water.
  - ✓ Thickening/lignification gives the vessels additional strength and prevents the walls from curving in.
- There are 3 main types of thickening lignification, i.e. annular, spiral and reticulate thickening.

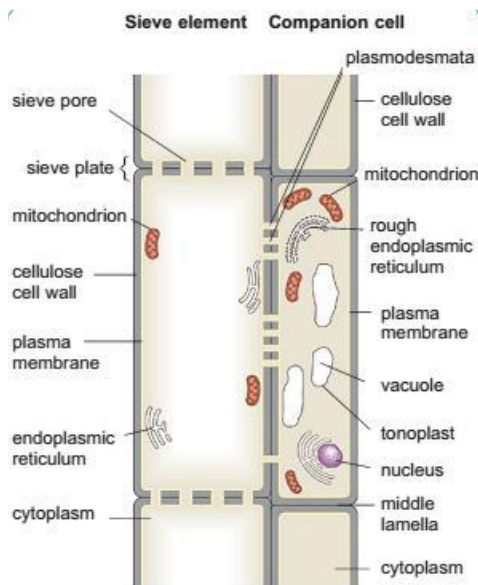


### PHLOEM TISSUE

- ✓ Comprises of parenchyma, sclerids and fibres with specialized cells for translocation known as sieve tube elements and companion cells.

- ✓ Long sieve tubes are formed by fusion of the sieve tube elements and the partial breakdown of the cross walls between them to form sieve plates and sieve pores.
- ✓ Their cell walls are thickened with cellulose and pectin together with lignin.
- ✓ Phloem cells lack nuclei and the cytoplasm is confined in a companion cell with a nucleus.
- ✓ Sieve elements and companion cells are connected to each other by plasmodesmata. Each sieve element forms a cell whose nucleus disintegrates during development. Its end walls known as the sieve plates are perforated by numerous pores (sieve pores) which allow the passage of materials from one sieve element to the next.
- ✓ The inside of the sieve elements contains fine cytoplasmic filaments, mitochondria, plastids and or any other organelles that may persist adjacent to the cell wall.
- ✓ Close to the sieve elements are companion cells which possess a nucleus, endoplasmic reticulum, ribosomes and mitochondria. They are metabolically active and all energy needed for translocation in the sieve elements is derived from here.

### Structure of the phloem tissue



Note: Sieve elements have no nucleus, tonoplast or ribosomes.

### LEVELS OF ORGANISATION IN ORGANISMS

Animals are more complex in tissue organization than plants on the fact that they lack the ability to perform chemical processes of photosynthesis.

#### Organ and organ systems

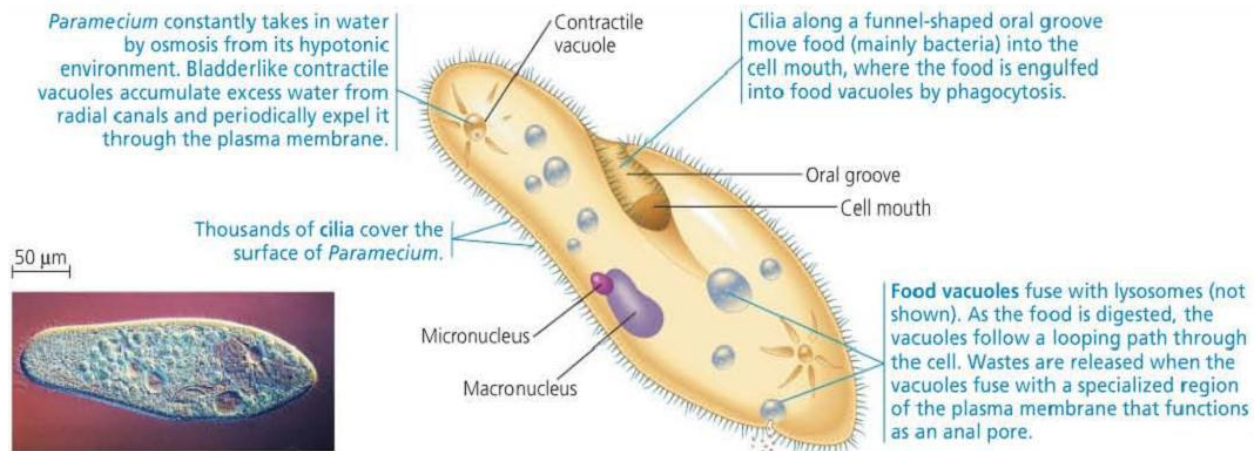
Organs are structurally distinct parts of the body made up of several types of tissues performing a particular function e.g. the kidney contains blood, smooth muscles, connective tissues and several types of epithelial tissues all combined to carry out excretion. Several organs which perform a specific function form an organ system, for example, the digestive system is made up of the gut and various accessory glands like pancreas and the liver. Sometimes an organ belongs to more than one system like the pancreas is found in the digestive system playing an important role in digestion and also in the endocrine system. Animals have elaborate organs and organ systems as compared to plants; however the plants have the leaves as organs for photosynthesis and flowers as reproductive organs. Other organs include the bulbs and corms which are storage or vegetative organs.

## Multicellular and unicellular organization

In **unicellular organisms**, the single cell has to carry within it self all functions that in a **multicellular organism** are performed by differentiated tissues and organs. Organelles in unicellular organisms e.g. paramecium take over the functions carried out by organs in multicellular organisms.

### Diagram of paramecium (unicellular)

▼ **Figure 28.11** Structure and function in the ciliate *Paramecium caudatum*.



Cilia are responsible for movement and sweeping food into the oval vestibule and food vacuoles formed at the base of the cytopharynx.

Digestion occurs in the cytoplasm and undigestible remains are expelled through the cytoproct.

The contractile vacuole carries out osmoregulation while the trichocysts contain needle-shaped threads that are for defense.

Therefore, the organization of the body of paramecium tends to be as efficient as the organ level of multicellular organization.

Functioning of multicellular organisms needs to be coordinated therefore some animals must have more than one cell but when this occurs independently it is referred to as a colony of single cells e.g. in sponges.

Hydra represents a group of primitive multicellular organisms. It has a few types of cells which engulf food and carries out movements and the stinging cell (nematoblast) for defense and killing their prey. These cells are connected by nerve cells and therefore coordinating its activities.

### Diagram of tissue of hydra (multicellular)

(Diagram in FA page 44)

Hydra has a tissue level of organization. Multicellular organization increases the size of the organism and allows specialization where different functions are carried out by different cells which permit greater efficiency and organisms become less environmental dependent. However, the cells lose their ability to exist on their own so they become increasingly dependent on one another's activities and as the number of cells increase, difficulties of acquiring oxygen and food materials by the individual cells also increase.

\*\*\*

***END.***

SCOBBA 2020